

See discussions, stats, and author profiles for this publication at: <https://www.researchgate.net/publication/362478204>

The Synergy of Photobiomodulation and Myofascial Release in Upper Limb Injuries – Case Series

Article · August 2022

CITATIONS

0

READ

1

2 authors:



Antonio Eduardo De Aquino Junior

University of São Paulo

29 PUBLICATIONS 200 CITATIONS

[SEE PROFILE](#)



Vitor Panhoca

University of São Paulo

32 PUBLICATIONS 212 CITATIONS

[SEE PROFILE](#)

Some of the authors of this publication are also working on these related projects:



Posdoc [View project](#)



Obesity and Photobiomodulation [View project](#)

Case Report

Open Access

The Synergy of Photobiomodulation and Myofascial Release in Upper Limb Injuries – Case Series

Ana Carolina Negraes Canelada^{1,3}, Antonio Eduardo de Aquino Junior^{1,2*}, Fernanda Mansano Carbinatto^{1,2}, Vitor Hugo Panhóca¹, Gabriel Simão^{1,2}, Letícia Zangotti^{1,2} and Vanderlei Salvador Bagnato^{1,4}

¹Institute of Physics of Sao Carlos, University of Sao Paulo, Sao Carlos, Sao Paulo, Brazil

²Clinica MultFISIO Brazil, Sao Carlos, Sao Paulo, Brazil

³Postgraduate Program in Biotechnology, Federal University of Sao Carlos, Sao Paulo, Brazil

⁴Hagler Institute for Advanced Study, Texas A&M University, Texas, United States of America

Abstract

The increase in repetitive strain injuries in recent years has led to the emergence of an epidemic character, which has become a very prevalent health problem in the contemporary world. This increase in cases comes from factors related to these pathologies directly linked to the modernization of work. As a means of intervention, this work presents the synergy of photobiomodulation and myofascial release. The myofascial release technique, which consists of a type of massage, which applies a deep slide, muscle compressions and frictions on the skin that act by mobilizing the muscle fascia. Photobiomodulation has direct action with analgesic and anti-inflammatory emphasis, as well as the formation of greater amounts of energy, helping diseased cells and organisms to return to homeostasis. Five patients were treated with pain in the cervical spine, shoulder, trapeze, elbow and carpal tunnel regions. The protocol used consisted of 10 treatment sessions, twice a week, for 15 minutes each session, using an 808nm therapeutic laser. The Disabilities of the arm, shoulder and hand questionnaire (DASH) and Visual Analogue Scale (VAS) were used. There was a great evolution in the values of The Disabilities of the arm, shoulder and hand questionnaire and Visual Analogue Scale, showing that the proposed treatment is an efficient, non-invasive and non-pharmacological form of treatment.

Keywords: Photobiomodulation; Myofascial Release; Pain

Introduction

Repetitive strain injuries have increased a lot in recent years, assuming an epidemic character, representing a very prevalent health problem in the current world, affecting different categories of workers. Due to the increase in cases, the factors considered for these pathologies come from the modernization of work. Modern work is characterized by mechanization, fragmentation, specialization and automation of industrial tasks and computerization in service areas [1, 2].

Workers make less effort to perform their tasks, but the movements are repeated and often static, always overloading the same muscle group, by maintaining a posture that is sometimes inadequate and for long periods of time. This behavior, associated with other predisposing factors, can lead to the development of work-related musculoskeletal disorders.

These diseases are injuries that affect muscles, joints, nerves, tendons, fascia and ligaments. Being classified as tendinitis, lateral and medial epicondylitis, neck pain, myofascial trigger points and carpal tunnel syndrome, among others.

They appear slowly, with bearable pain, they can be confused with tiredness, but over time they lead to more intense discomfort, such as sharp and continuous pain, with sensations of tingling and numbness, which can aggravate the problem, characterizing due to chronic pain, difficult to treat, mainly affecting the neck, shoulder girdle and upper limbs. It is very common to have pain, inflammation, decreased strength, fatigue of the affected site, with tension, muscle contracture and alteration of joint mobility [3-5], and the worker may, after some time, be temporarily away from activities or, in some more serious cases, permanently [6].

According to the Australian Bureau of Statistics, in 1980 and 1981, there was a major occupational health problem in Australia where the statistical profile of diseases and accidents that affected the upper limb

was due to repetitive movements [7]. With that physiotherapy plays an important role in addressing repetitive strain injuries, where they are responsible for carrying out preventive, corrective or rehabilitative activities.

Resources such as: thermotherapy, electrotherapy, manual techniques, are important for the control of patients' pain, providing an improvement in the painful condition of the inflammatory response, reducing edema, improving circulatory conditions, relaxing the muscles, and easing the pain of these patients. permeating functional improvement [8].

Through the action of light in electrotherapy, photobiomodulation has been cited in the literature, presenting a photobiomodulatory effect and being indicated in cases of pain, inflammation and tissue repair [9].

Photobiomodulation leads to the emission of photons that reach the mitochondria, increasing energy synthesis (ATP), and the cell membranes of fibroblasts, keratinocytes and endothelial cells, allowing the absorption of light energy by cellular chromophores and converting it into chemical kinetic energy inside the cell [10, 11], resulting in the formation of numerous blood vessels, thus improving the amount of oxygen in the tissues, in the increased production of granulation

***Corresponding author:** Antonio Eduardo de Aquino Junior, Institute of Physics of Sao Carlos, University of Sao Paulo and Clínica MultFISIO Brazil, Sao Carlos, Sao Paulo, Brazil, E-mail: antonioaquino@ifsc.usp.br

Received: 29-Mar-2022, Manuscript No. jnp-22-58951; **Editor assigned:** 31-Mar-2022, PreQC No. jnp-22-58951(PQ); **Reviewed:** 14-Apr-2022, QC No. jnp-22-58951; **Revised:** 20-Apr-2022, Manuscript No. jnp-22-58951(R); **Published:** 27-Apr-2022, DOI: 10.4172/2165-7025.1000515

Citation: Canelada ACN, Junior AEA, Carbinatto FM, Panhóca VH, Simão G, et al. (2022) The Synergy of Photobiomodulation and Myofascial Release in Upper Limb Injuries – Case Series. J Nov Physiother 12: 515.

Copyright: © 2022 Canelada ACN, et al. This is an open-access article distributed under the terms of the Creative Commons Attribution License, which permits unrestricted use, distribution, and reproduction in any medium, provided the original author and source are credited.

tissue, stimulating muscle relaxation and thus contributing to the analgesic effects of laser therapy [12, 13]. And with this acceleration of microcirculation, cytokines are released that reduce the inflammatory reaction, and the reabsorption of edema, eliminating the accumulation of intermediate metabolites [14].

Another treatment for repetitive strain injuries is the myofascial release technique, which consists of a type of massage, which applies a deep slide, muscle compressions and frictions on the skin that act by mobilizing the fascia [15].

The myofascial release acts on muscle spindle cells, which respond with a reflex contraction to rapid stretches, and on the Golgi Tendon Organs (GTO), which is a mechanoreceptor found at the muscle-tendon junction, responsible for capturing proprioceptive information, through neural pathways, verifying the level of tension that is within the muscle and/or tendon group. When tension builds to the point of high risk of injury, OTG stimulates muscle spindles to relax the muscle in question. This reflex relaxation is autogenic inhibition, providing passive relaxation and stretching, thus allowing greater range of motion and decreased pain [16].

Thus, the objective of this case study was to perform a treatment for the pathologies of repetitive injuries, such as tendinitis, lateral and medial epicondylitis, neck pain, myofascial trigger points and carpal tunnel syndrome, using the synergistic action of laser and myofascial release, offering an instrumental therapeutic approach, with mechanical effects in conjunction with the action of light, to minimize symptoms of pain, inflammation, stiffness and loss of function in patients joints.

Materials and Methods

Technology: The development of the project was approved by the Ethics Committee for Human Beings of the Santa Casa de Misericórdia of São Carlos, under the number CAAE 40296320.5.0000.8148 and CAAE 55137522.4.0000.8148, in accordance with resolution 466/2012 and resolution 510/2016.

The equipment is a myofascial laser prototype, which was developed by the São Carlos Institute of Physics (IFSC) and MMOptics, São Carlos, São Paulo, Brazil. The device has in its geometry, two spheres at the ends, which with the mechanical action provides the compression of the muscle with the help of the spheres, together with the circular movements carried out by them, rubbing the skin, and a deep sliding, covering the entire length of the muscle, together with the action of light, adjusting the wavelength and time that will be applied on the device's display (Figure 1).

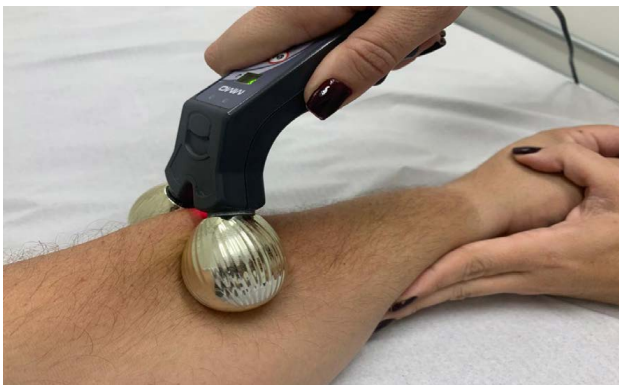

Figure 1: It is possible to observe the spheres at the ends responsible for the myofascial release process and the action of photobiomodulation performed by the laser at the center of the equipment.

Evaluation: Five patients were evaluated, four female patients and one male patient, with repetitive strain injuries in the upper limbs. The evaluation and application of the therapy was carried out at the Clínica MultFISIO Brazil, in the city of São Carlos-SP, in the anamnesis the following questionnaires were applied: Questionnaire for the Assessment of Musculo-Skeletal Symptoms, which consists of personal and professional questions of the patient; Dysfunctions of the Arm, Shoulder and Hand, which aims to measure symptoms and function in individuals with musculoskeletal pathologies in the upper limbs, focusing on physical function and the individual's health status and finally, the Visual Analogue Scale (VAS), which consists of helping to measure the intensity of pain during treatment.

Cases, Protocol and Application Sites: The subjects underwent the combined application of mechanical effects with the myofascial release technique, which was exerted in a proximal to distal direction (in the direction of the origins to the muscular insertions). Photobiomodulation was performed with a wavelength of 808nm. The application sites of the therapy under study were submitted through the appropriate pathologies, classified into shoulder tendinitis, lateral and medial epicondylitis, neck pain, myofascial trigger point and carpal tunnel syndrome, performing the course in the muscles and tendons injured by overuse of the member. There were 10 treatment sessions, twice a week, lasting 15 minutes in each session, regardless of the application site.

Case 1 - Cervical Spine

Patient, female, Caucasian, 44 years old, diagnosed with neck pain. She reported that she has been working with typing for 8 years in a company. As an in-house salesperson, she has to meet financial goals, experiencing a lot of tension and pain in her cervical region. Regarding the evaluation mechanism, the Arm, shoulder and hand disorders (DASH) and the Visual Analogue Scale (VAS) were used. Assessments were performed in relation to before/after treatment. There were 10 sessions, twice a week. It was submitted to photobiomodulation with a wavelength of 808nm, and mechanical action in the entire direction of the origins and insertions of the tendons of the affected posterior muscles in the region of the cervical spine.

Case 2 - Shoulder

Patient, female, Caucasian, 51 years old, diagnosed with rotator cuff tendinitis in the left shoulder. She reported that she has worked in a company for 11 years, and due to the repetitive and straining movements performed, she had pain and inflammation in the shoulder tendons. Regarding the evaluation mechanism, the Arm, shoulder and hand disorders (DASH) and the Visual Analogue Scale (VAS) were used. Assessments were performed in relation to before/after treatment. There were 10 sessions, twice a week. It was submitted to photobiomodulation with a wavelength of 808nm, and mechanical action in the entire direction of the origins and insertions of the tendons of the affected muscles that make up the rotator cuff.

Case 3 - Trapeze

Patient, female, Caucasian, 27 years old, diagnosed with myofascial trigger points. She reported that she has been working with typing for 3 years in a company, and suffers a lot of pain, muscle tension with hypersensitive nodules in the middle trapezius muscle in the scapular region. Regarding the evaluation mechanism, the Arm, shoulder and hand disorders (DASH) and the Visual Analogue Scale (VAS) were used. There were 10 sessions, twice a week. He was submitted to

photobiomodulation with a wavelength of 808nm, and mechanical action in the entire direction of the affected middle trapezius muscle tendon in the scapular region.

Case 4 - Elbow

Patient, female, Caucasian, 41 years old, diagnosed with bilateral lateral and medial epicondylitis. She reported that for 10 years she has been self-employed with domestic services. Due to the repetitive movements and efforts performed, she presented pain and inflammation in the flexor and extensor tendons of the forearm. Regarding the evaluation mechanism, the Arm, shoulder and hand disorders (DASH) and the Visual Analogue Scale (VAS) were used. There were 10 sessions, twice a week. He was submitted to photobiomodulation with a wavelength of 808nm, and mechanical action in the whole direction of the tendons of the affected forearm flexor and extensor muscles in both elbows.

Case 5 - Carpal Tunnel

Patient, male, Caucasian, 38 years old, diagnosed with Carpal Tunnel Syndrome in the right wrist. He reported that he has been working with typing in a company for 4 years and due to the repetitive movements, he presented pain, inflammation, tingling in the wrist and hand region and also trigger finger in the 2nd and 3rd fingers of the right hand. Regarding the evaluation mechanism, the Arm, shoulder and hand disorders (DASH) and the Visual Analogue Scale (VAS) were used. He was submitted to photobiomodulation with a wavelength of 808nm, and mechanical action in the whole direction of the tendons of the affected forearm flexor muscles.

Results

Figure 2 shows the difficulty in performing activities in reported cases: cervical spine, shoulder, trapeze, elbow and carpal tunnel, in relation to before/after treatment. It is possible to observe that in all comparisons in difficulty in performing activities they show a reduction above 60%.

Figure 3 illustrates the assessment of Disabilities of the arm, shoulder and hand questionnaire (DASH), when the intensity of symptoms of pain, weakness, stiffness and paresthesia, in relation to before/after treatment, is observed. All values observed showed a decrease in symptoms in a range of 57% to 67%.

Figure 4 provides a visualization of the variable commitment of social activities in relation to cervical spine, shoulder, trapeze, elbow and carpal tunnel. These values point to a reduction of this variable between 66% and 76%, according to the region of treatment.

Figure 5 shows the difficulty to sleep, when evaluating the before/after relationship of the cervical spine, shoulder, trapeze, elbow and carpal tunnel regions. It is possible to observe a reduction of 66% in all treatment regions, with the exception of the elbow, which did not change.

Figure 6 illustrates the psychological commitment in the relationship before/after the treatment of the treated regions. A 66% reduction in psychological commitment in the cervical spine, shoulder and trapeze is observed. In relation to the elbow and carpal tunnel, no change was observed.

Figure 7 shows the total evolution values of the Disabilities of the arm, shoulder and hand questionnaire (DASH), in the ratio before/after treatment. We observed a reduction of 63% in cervical spine, 66% in shoulder, 63% in trapeze, 38% in elbow and 38% in carpal tunnel.

Figure 8 shows the visual analogue scale in relation to cervical spine, shoulder, trapeze, elbow and carpal tunnel, in condition before/after treatment. A reduction of 40% in cervical spine, 60% in shoulder, 35% in trapeze and 50% in carpal tunnel is observed. The value of trapeze showed no change.

Discussion

New forms of treatment have greatly helped the treatment of pain and chronic diseases in recent years, such as fibromyalgia [17, 18], arthrosis [19], Psoriatic Arthritis [20], temporomandibular joint

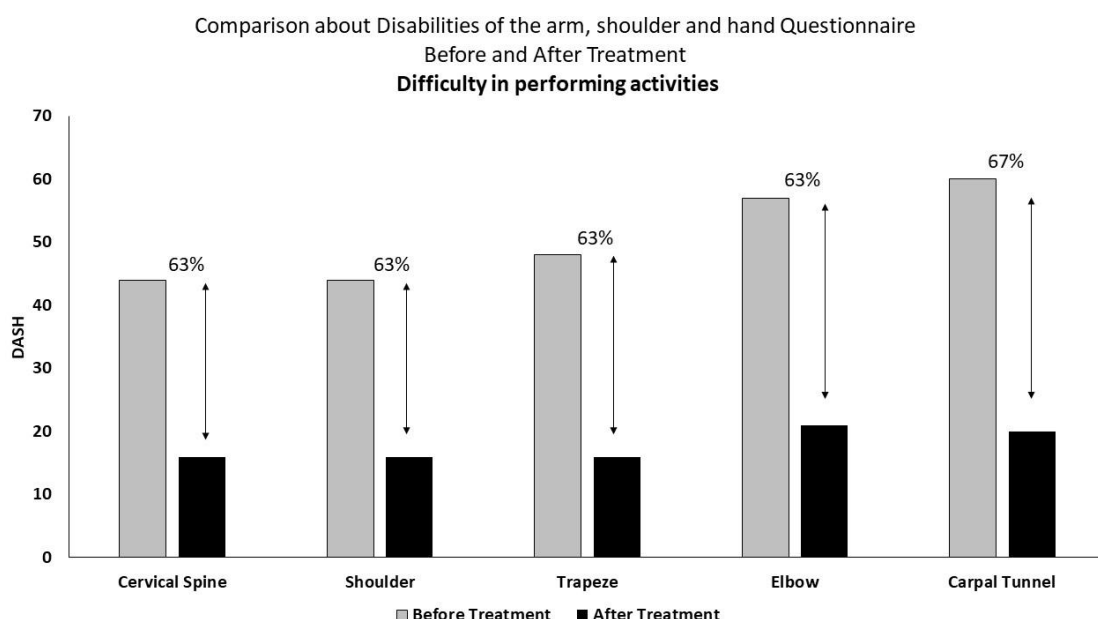


Figure 2: DASH - Arm, shoulder and hand deficiencies, represented on average, applied in relation to the cervical spine, shoulder, trapeze, elbow and carpal tunnel regions. Data are presented with percentage difference, showing values before and after treatment in relation to difficulty in performing activities.

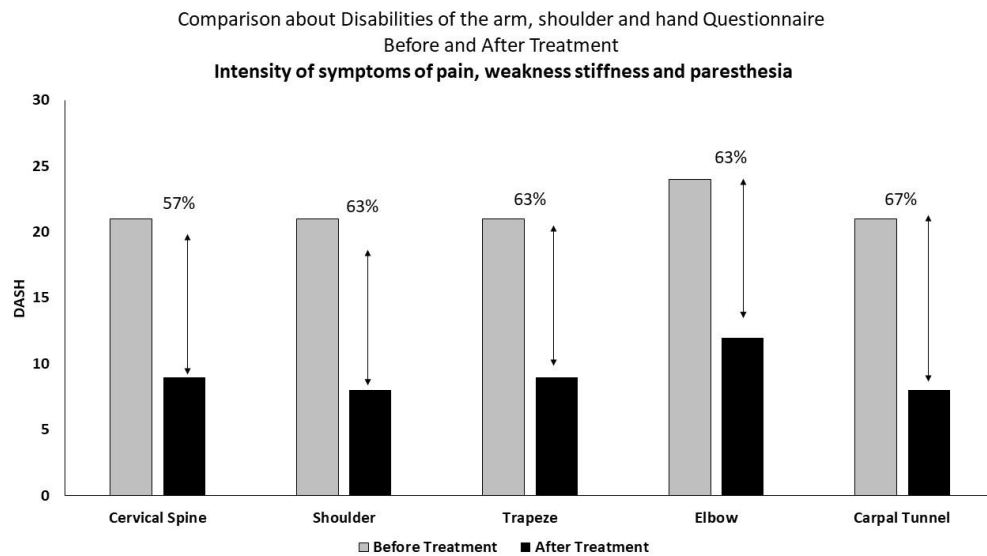


Figure 3: DASH - Arm, shoulder and hand deficiencies, represented on average, applied in relation to the cervical spine, shoulder, trapeze, elbow and carpal tunnel regions. Data are presented with percentage differences, showing values before and after treatment in relation to intensity of symptoms of pain, weakness, stiffness and paresthesia.

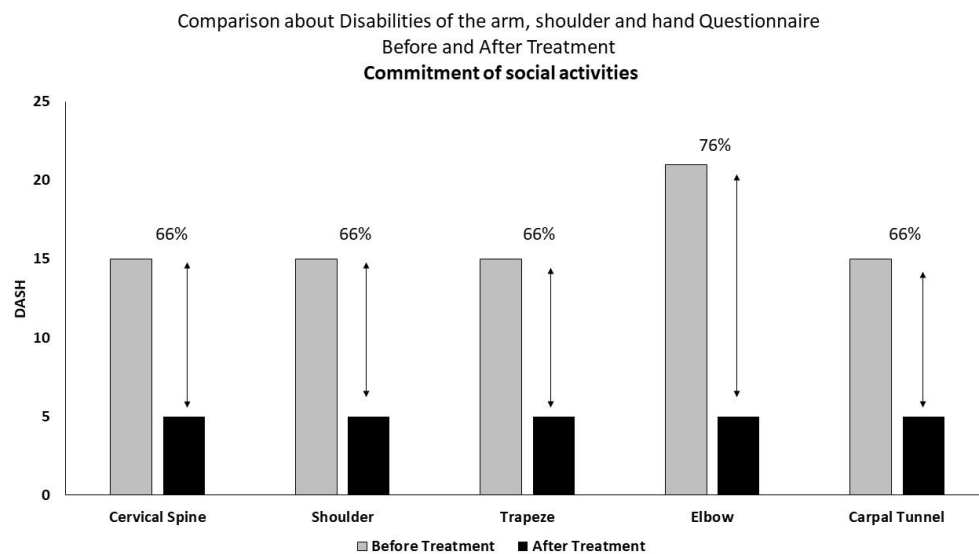


Figure 4: DASH - Arm, shoulder and hand deficiencies, represented on average, applied in relation to the cervical spine, shoulder, trapeze, elbow and carpal tunnel regions. Data are presented with percentage differences, showing values before and after treatment in relation to commitment of social activities.

[21], Parkinson [22] and recently adhesive capsulitis [23], in a new technology and methodology that reduced the average treatment time from 3 years to approximately 45 days. Within this context, the treatment of repetitive strain injuries through new technological and methodological actions is of great importance. In this way, the association of photobiomodulation with myofascial release demonstrated great therapeutic action in a study of adhesive capsulitis [23], transforming the way of treating the lesion. The synergy of this treatment model has important actions. Photobiomodulation, a resource widely used singularly in physiotherapy, promotes anti-inflammatory and analgesic action, which, through a process of enzymatic modulation, promotes the formation of a greater production of ATP, in addition to having a positive effect on the synthesis of proteins and cell proliferation [24, 25]. All this provides a condition of homeostasis in cells or organisms in a state of suppression or disease [25]. In turn, myofascial release applies a deep slide, muscle compressions and skin friction, which acts

directly on the muscle fascia [15], acting on fusiform muscle cells and, therefore, through reflex contractions to rapid stretching, it promotes a passive relaxation and stretching effect, positively influencing stretching and pain reduction. Thus, a synergistic technology that enables the combination of myofascial release system and photobiomodulation brings with it the condition of muscle fascia reorganization and muscle pain relief.

Cervical spine, as a musculoskeletal dysfunction, generates pain, inflammation, burning and limitation in the range of motion of the cervical region. The cervical region is comprised between the base of the occiput and the cervicothoracic region and the cervical muscles comprise in the anterolateral muscles, posterior muscles (superficial - trapezius muscle, intermediate - splenius muscle of the head and splenius cervical muscle, and deep - muscle semispinatus of the head, semispinatus muscle of the neck, multifidus muscles and in the

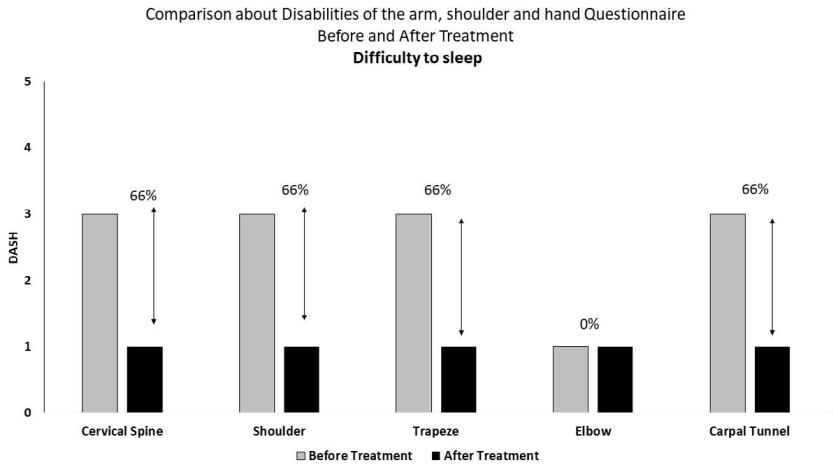


Figure 5: DASH - Arm, shoulder and hand deficiencies, represented on average, applied in relation to the cervical spine, shoulder, trapeze, elbow and carpal tunnel regions. Data are presented with percentage differences, showing values before and after treatment in relation to difficulty to sleep.

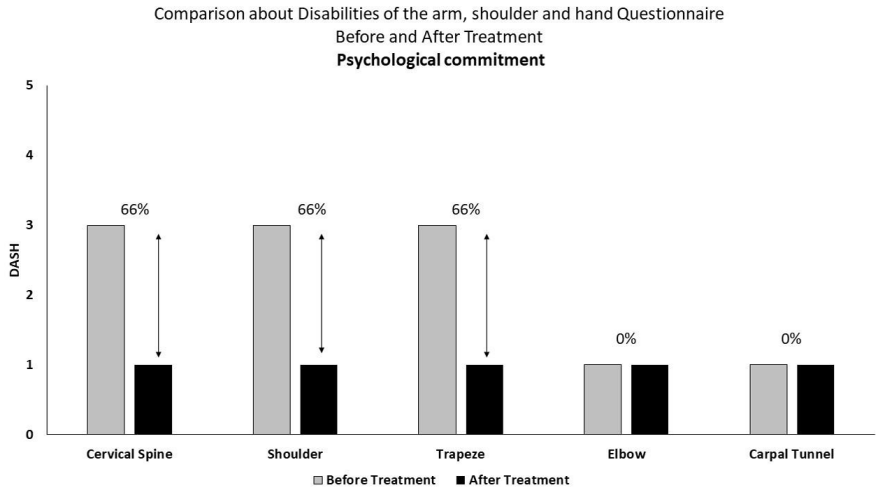


Figure 6: DASH - Arm, shoulder and hand deficiencies, represented on average, applied in relation to the cervical spine, shoulder, trapeze, elbow and carpal tunnel regions. Data are presented with percentage differences, showing values before and after treatment in relation to psychological commitment.

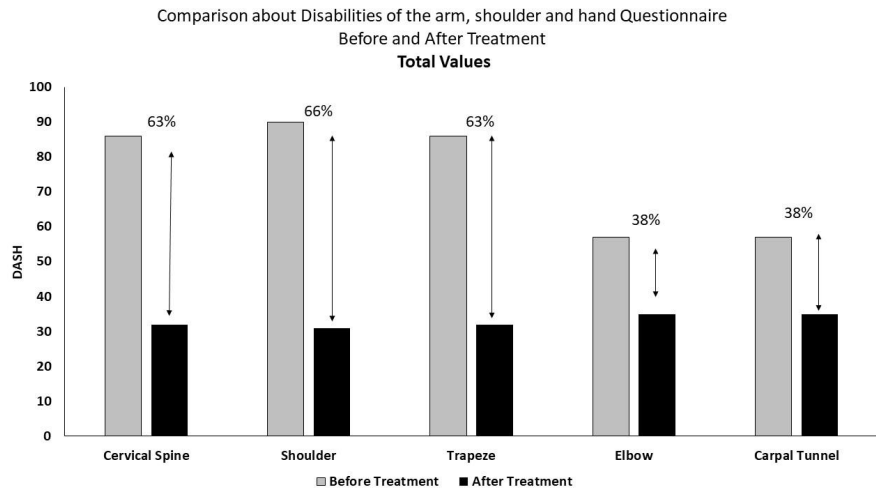
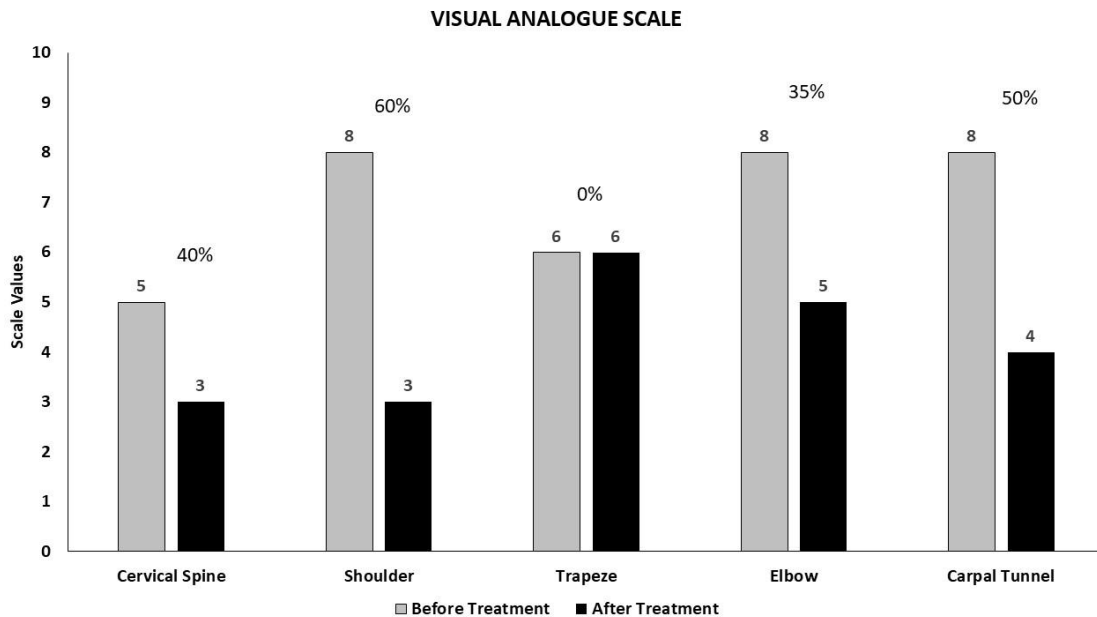


Figure 7: DASH - Arm, shoulder and hand deficiencies, represented on average, applied in relation to the cervical spine, shoulder, trapeze, elbow and carpal tunnel regions. Data are presented with percentage differences, showing values before and after treatment in relation to total values.



short and long rotator muscles [26]. Such action of the synergy of the resources used can be observed in figures 2, 3, 4, 5, 6 and 7, regarding the Disabilities of the arm, shoulder and hand questionnaire (DASH), in the ratio before/after treatment. It is possible to observe the evolution of the values considered for difficulty in performing activities (63%), intensity of symptoms of pain, weakness stiffness, and parestheria (57%), commitment of social activities (66%), difficulty of sleep (66%), physicalological commitment (66%) and total values (40%). Furthermore, the visual analogue scale (Figure 8), which represents the level of pain, showed a reduction of 40%.

Shoulder Tendinitis, an inflammation of the tendon, has pain as one of the main symptoms, with supraspinatus tendinitis being the most frequent cause, although any other tendon that makes up the rotator cuff can influence the inflammation in the shoulder. The rotator cuff (infraspinatus muscle, subscapularis muscle, teres minor muscle and tendons) involve the shoulder joint, with joint mobilization function [27]. By observing figures 2, 3, 4, 5, 6 and 7, it is possible to analyze the action of the resources used, in relation to the Disabilities of the arm, shoulder and hand questionnaire (DASH), in the ratio before/after treatment. A reduction in values is observed for difficulty in performing activities (63%), intensity of symptoms of pain, weakness stiffness, and parestheria (63%), commitment of social activities (66%), difficulty of sleep (66%), physicalological commitment (66%) and total values (66%). When observing the visual analogue scale (figure 8), pain reduction was shown to be 60%.

Myofascial Trigger Points are alterations or injuries in myofascial structures associated with palpation of a hypersensitive nodule, formed by trauma, repeated microtraumas of musculoskeletal structures, overloads, excess muscle tension, inadequate postures, ergonomic factors, psychological stress and joint dysfunction [28, 29]. In the analysis of the Disabilities of the arm, shoulder and hand questionnaire (DASH), in figures 2, 3, 4, 5, 6 and 7, myofascial release associated with photobiomodulation, in relation to the before/after treatment ratio, showed a reduction in the values for difficulty in performing activities (63%), intensity of symptoms of pain, weakness stiffness, and parestheria (63%), commitment of social activities (66%), difficulty

of sleep (66%), physicalological commitment (66%) and total values (63%). However, myofascial release of trigger points can be painful, which may have caused the pain evolution to fail according to the visual analogue scale (figure 8).

Lateral epicondylitis, an inflammation that occurs at the origin of the extensor tendons of the wrist and fingers, where all these muscles are innervated by the radial nerve. Medial epicondylitis, also an inflammation, in the tendons of the flexor muscles of the wrist and fingers, are innervated by the median nerve. During lateral epicondylitis, the tendons and the extensor muscle are damaged by overuse [30]. The results presented in the analysis of figures 2, 3, 4, 5, 6 and 7, is pointed out in the relationship before/after treatment, the reduction of values for difficulty in performing activities (63%), intensity of symptoms of pain, weakness stiffness, and parestheria (63%), commitment of social activities (76%), difficulty of sleep (0%), physical commitment (0%) and total values (38%). Visual analogue scale analysis showed a 35% reduction in pain (figure 8).

Carpal tunnel syndrome is located in the wrist region, in a narrow tunnel, where the median nerve passes, which, when it becomes even narrower, swells, due to repetitive movements, causing nerve compression, providing symptoms of pain, numbness, tingling, locking of the fingers and weakness in the hand [31]. The evaluation carried out in figures 2, 3, 4, 5, 6 and 7 shows the reduction of values for difficulty in performing activities (67%), intensity of symptoms of pain, weakness stiffness, and parestheria (67%), commitment of social activities (66%), difficulty of sleep (66%), physical commitment (0%) and total values (38%), in the relationship before/after treatment. The evolution of pain was reduced by 50% according to visual analogue scale (figure 8).

The realignment of nerve fibers and release of muscle fascia promotes an appropriate situation to improve the condition of joint or muscle movement involved, regardless of the treated region. Also, when associated with photobiomodulation, the condition of returning to joint and tissue homeostasis²⁰, through the beneficial actions of light, in relation to analgesia and anti-inflammatory potential, as well as the production of a greater amount of ATP, allow the return of diseased

tissue or in a state of suppression²⁵, to its functionality and fullness.

Treatment applying photobiomodulation with myofascial release appears as a complementary or alternative treatment in patients who have a contraindication to drug treatment. Thus, new technologies are essential for new treatments to be performed, enabling patients to have a better quality of life, without the use of drugs and without invasive processes.

Conclusion

The synergistic action of physiotherapeutic resources is no longer a promising issue, but a reality. The synergistic action of myofascial release proves to be a positive resource, promoting the improvement of patients' quality of life, without the need for pharmacological or invasive intervention. The realization of new technologies in this spectrum are the path that public health must follow in order to increase the quality and efficiency of the therapeutic result.

Ethical Approval

This study was approved by the Research Ethics Committee and the National Research Ethics Committee through CAAE 40296320.5.0000.8148 and CAAE 55137522.4.0000.8148.

Acknowledgement: Not applicable.

Conflicts of Interest: All authors confirm that there is no conflict of interest.

References

1. Putz-Anderson V (2017) Cumulative trauma disorders. Taylor & Francis, London.
2. Ohara H, Aoyama H, Itani T (1976) Health hazard among cash register operators and the effects of improved working conditions. *J Hum Ergol* 5(1):31-40.
3. Van Galen GP (2007) Repetitive Strain Injury. *Cambridge Handbook of Psychology, Health & Medicine*.
4. Williams R, Westmorland M (1994) Occupational cumulative trauma disorders of the upper extremity. *Am J Occup Ther* 48(5):411-420.
5. Houvet P, Obert L (2013) Upper limb cumulative trauma disorders for the orthopaedic surgeon. *Orthop Traumatol: Surg Res* 99(1):S104-S114.
6. Jansson C, Alexanderson K (2013) Sickness absence due to musculoskeletal diagnoses and risk of diagnosis-specific disability pension: A nationwide Swedish prospective cohort study. *Pain* 154(6):933-941.
7. Gun RT (1990) The incidence and distribution of RSI in South Australia 1980-81 to 1986-87. *Med J Aust* 153(7): 376-380.
8. Millar K, Zakrevsky T, Bigwood S, Purdy C, Liston C (1986) The role of the physiotherapist in the management of repetitive strain injury. *Aust J Physiother* 32(3):170-180.
9. Enwemeka CS, Parker JC, Dowdy DS, Harkness EE, Harkness LE, et al. (2004) The efficacy of low-power lasers in tissue repair and pain control: a meta-analysis study. *Photomed Laser Ther* 22(4):323-329.
10. Hawkins D, Abrahamse H (2007) Changes in cell viability of wounded fibroblasts following laser irradiation in broad-spectrum or infrared light. *Laser Chem* 2007.
11. Chow RT, Johnson MI, Lopes-Martins RA, Bjordal JM (2009) Efficacy of low-level laser therapy in the management of neck pain: a systematic review and meta-analysis of randomised placebo or active-treatment controlled trials. *Lancet* 374(9705):1897-1908.
12. Smith KC (2005) Laser (and LED) therapy is phototherapy. *Photomed Laser Surg* 23(1):78-80.
13. Vladimirov YA, Osipov AN, Klebanov GI (2004) Photobiological principles of therapeutic applications of laser radiation. *Biochem* 69(1):81-90.
14. Zhang JM, An J (2007) Cytokines, inflammation and pain. *Int Anesthesiol Clin* 45(2):27.
15. Warren AJ, LaCross Z, Volberding JL, O'Brien MS (2020) Acute outcomes of myofascial decompression (cupping therapy) compared to self-myofascial release on hamstring pathology after a single treatment. *Int J Sports Phys Ther* 15(4):579.
16. Sartoyo S, Kasimbara RP, Fariz A (2021) The Effect of Myofascial Release Technique On Low Back Pain Changes. *Institute of Science and Health Technology of Malang, Malang, Indonesia*.
17. Junior AEA, Carbinatto FM, Franco DM, Bruno JSA, Simão MLS (2020) The Laser and Ultrasound: The Ultra Laser like Efficient Treatment to Fibromyalgia by Palms of Hands—Comparative Study. *J Nov Physiother* 11(2):1-5.
18. Aquino Jr AE, Carbinatto FM, Fernandes AC, Franco DM, Biffi de Lara AP, et al. (2021) The Combined Photobiomodulation and Therapeutic Ultrasound: How does the Efficient Treatment of Fibromyalgia by the Palms Promote a Prolonged Effect? *J Nov Physiother* 11(7):1-5.
19. De Souza Simão ML, Fernandes AC, Ferreira KR, De Oliveira LS, Mário EG (2019) Comparison between the Singular Action and the Synergistic Action of Therapeutic Resources in the Treatment of Knee Osteoarthritis in Women: A Blind and Randomized Study. *J Nov Physiother* 9(2):1-3.
20. Canelada ACN, Carbinatto FM, Junior AEA, Bagnato VS (2021) A Case Report on the Use of a Conjugated System of Myofascial Release for Shoulder Capsulitis. *J Nov Physiother* 11(2):1-4.
21. Panhóca VH, Nogueira MS, Bagnato VS (2020) Treatment of facial nerve palsies with laser and endermotherapy: a report of two cases. *Laser Phys* 18(1):15601.
22. Tamae PE, dos Santos AV, Simão MLS, Canelada ACN, Zampieri KR, et al. (2020) Can the associated use of negative pressure and laser therapy be a new and efficient treatment for Parkinson's pain? A comparative study. *J Alzheimers Dis Parkinsonism* 10:1-6.
23. Canelada ACN, Garcia V, Rodrigues TZ, de Souza VB, Panhóca VH, et al. (2022) Effect to the Synergistic Action of Photobiomodulation and Therapeutic Ultrasound on Psoriatic Arthritis and Fibromyalgia - Case Report. *J Nov Physiother* 12(2):1-4.
24. Çitak-Karakaya İ, Akbayrak T, Demirtürk F, Ekici G, Bakar Y (2006) Short and long-term results of connective tissue manipulation and combined ultrasound therapy in patients with fibromyalgia. *Manipulative Physiol Ther* 29(7):524-528.
25. Karu T (2010) Mitochondrial mechanisms of photobiomodulation in context of new data about multiple roles of ATP. *Photomed Laser Surg* 28(2):159-160.
26. Waxenbaum JA, Reddy V, Futterman B (2017) *Anatomy, back, thoracic vertebrae*. Stat Pearls Publishing, Treasure Island.
27. Gomoll AH, Katz JN, Warner JJ, Millett PJ (2004) Rotator cuff disorders: recognition and management among patients with shoulder pain. *Arthritis Rheumatol* 50(12), 3751-3761.
28. Fernández-de-las-Peñas C, Alonso-Blanco C, Fernández-Carnero J, Miangolarra-Page JC (2006) The immediate effect of ischemic compression technique and transverse friction massage on tenderness of active and latent myofascial trigger points: a pilot study. *J Bodyw Mov Ther* 10(1):3-9.
29. Travell JG, Simons DG (1983) *Myofascial pain and dysfunction: the trigger point manual. The upper half of body*. 2 Ed Lippincott Williams & Wilkins, Baltimore.
30. Google Scholar
31. Shirri R, Viikari-Juntura E (2011) Lateral and medial epicondylitis: role of occupational factors. *Best practice & research Clin rheumatol* 25(1):43-57.
32. Viera AJ (2003) Management of carpal tunnel syndrome. *Am Fam Physician* 68(2):265-272.